

# Skeletal and dental growth and development in chimpanzees of the Taï National Park, Côte D'Ivoire

A. L. Zihlman<sup>1</sup>, D. R. Bolter<sup>2</sup> & C. Boesch<sup>3</sup>

<sup>1</sup> Anthropology Department, University of California, Santa Cruz, CA, USA

<sup>2</sup> Anthropology Department, Modesto College, Modesto CA, USA

<sup>3</sup> Max-Planck Institute for Evolutionary Anthropology, Leipzig, Germany

## Keywords

immature Taï chimpanzees; juvenile age classes; dental eruption; skeletal growth.

## Correspondence

Adrienne L. Zihlman, Anthropology Department, University of California, 1156 High Street, Santa Cruz, CA 95064, USA.

Tel: +1 831 459 4467; Fax: +1 831 459 5900

Email: azihlman@ucsc.edu

Received 25 September 2006; accepted 11 December 2006

doi:10.1111/j.1469-7998.2007.00301.x

## Abstract

An extraordinary collection of 22 immature skeletons from Taï National Park, Côte d'Ivoire, has provided a rare opportunity to establish the timing of dental eruption and its correlation with skeletal fusion and morphometrics in wild chimpanzees of known chronological ages. Comparison of the immature Taï chimpanzees *Pan troglodytes verus* with adults from the same population show that sex differences in skeletal maturation apparently appear during the Juvenile II stage, about age 8. A few skeletons from other chimpanzee field sites conform to the dental and skeletal growth in Taï chimpanzees. The tempo of wild chimpanzee growth contrasts sharply with the rate demonstrated for captive individuals. Captive chimpanzees may mature as much as 3 years earlier. The ability to link physical development with field observations of immature chimpanzees increases our understanding of their life-history stages. These data provide an improved dataset for comparing the rates of growth among chimpanzees, *Homo sapiens* and fossil hominids.

## Introduction

Chimpanzee dental development and skeletal growth provide a basis for monitoring the tempo of life stages within the species and for assessing the evolution of human life history (e.g. Schultz, 1940, 1963, 1969; Bogin, 1999; Bolter & Zihlman, 2007). The first systematic and longitudinal studies on chimpanzee dentition, linear dimensions and body mass have necessarily been carried out in captivity where individuals' ages are known (e.g. Schultz, 1940; Gavan, 1953, 1971; Nissen & Riesen, 1964; Kerley, 1966; Watts, 1971; Conroy & Mahoney, 1991; Hamada *et al.*, 1996; Kuykendall, 1996; Leigh & Shea, 1996). Under captive conditions, food is provided, activity is limited and predators are absent. In the wild, chimpanzees range widely for food, are physically active climbing trees and interacting with other group members and are under constant threat of predation. These differences in food, activity and predation between captive and wild chimpanzees may affect the timing of tooth emergence and sexual maturity (Nishida, 1990; Tutin, 1996; Boesch & Boesch-Achermann, 2000; Zihlman, Bolter & Boesch, 2004).

Very little has been recorded about growth and development in wild chimpanzees of known chronological ages and sex (cf. Kimura & Hamada, 1996). Timing of dental emergence, testicular development and body mass have rarely been documented for wild chimpanzees, with the noted

exception of Gombe chimpanzees (Pusey, 1978, 1990; Pusey *et al.*, 2005). Only a few reports on skeletons of known-age individuals are available (e.g. Yasui & Takahata, 1983; Matsuzawa *et al.*, 1990; Zihlman, Morbeck & Goodall, 1990; Kimura & Hamada, 1996; Hamada & Usono, 2002).

Here, we report on an extraordinary set of 22 immature wild chimpanzees from the Taï National Park, Côte d'Ivoire *Pan troglodytes verus*. The collection represents most age and sex classes; in addition, a sample of adults ( $n = 25$ , including four young adults) provides a comparative basis with these immatures. For the first time, it is possible in a series of wild immature chimpanzees to correlate chronological age with hard tissue markers of growth and to make comparisons with available skeletons from other research sites and with captive chimpanzees. These data suggest a re-evaluation of the value of captive data for understanding the biology of chimpanzees and their implications for hominid evolution. We hypothesize that the role of energy required for growth and development of wild juvenile chimpanzees needs to be reconsidered.

## Materials and methods

### The sample

During daily follows of target individuals from the habituated communities among the Taï chimpanzees (Boesch &

Boesch-Achermann, 2000; Herbinger, Boesch & Rothe, 2001), we might happen to encounter a fresh dead chimpanzee body. If the decomposition was not too advanced, identification was made and corroborated with absence of that individual in the study group. At the same time, the cause of death was determined as precisely as possible (Boesch & Boesch-Achermann, 2000; Leendertz *et al.*, 2006). Some animals died from Ebola, accidents such as falls or were killed by leopards, but in many instances the cause of death is unknown. Behavioral signs of disease or injuries leading to death are extremely rare in Taï chimpanzees, and no signs of malnutrition have been observed. Therefore, we tend to think that, even when the cause of death was not known, it did not result from chronic illness. If the death was very recent, we left the carcass untouched to observe other chimpanzees' responses to death (see Boesch & Boesch-Achermann, 2000). To speed up the decomposition process of older carcasses and prevent disease transmission, bones were buried in the ground and retrieved once decomposition was completed. After Ebola outbreaks (Le Guenno *et al.*, 1995; Formenty *et al.*, 1999), the decomposed bodies were removed months later. For those known to have died from Ebola, the bones were boiled in javel water for 1 hour. The sample was collected over a 19-year period, and many individuals were members of social groups under study. Skeletal remains from the forest floor were then labeled and stored in the field research station. All skeletal remains were exported to Zürich with corresponding CITES export permits.

The skeletal sample from Taï consists of partial to relatively complete remains of 22 immature individuals. Most are of known sex and age, and range from 3 weeks to 13.5 years. One female (Juvenile II) and one male (Juvenile III) are of unknown age, and three individuals are unknown in sex and age. The ages of these four individuals are estimated from dental emergence chronologies of known-age immatures. Animals older than 10 years ( $n = 6$ ) are known only to year of birth and their ages at death are therefore estimated to the half-year (Boesch & Boesch-Achermann, 2000). Four skeletons are incomplete and 18 are fairly complete. Of these 18, most skeletal elements have survived, although hand and foot bones are commonly missing; the three unknown individuals are missing pelvic material. In addition, four young adults are added to the sample to clarify skeletal maturation patterns; two 14.5-year-old male skeletons and one age 16.5 female skeleton partially complete, and a complete female specimen, age 19.5.

## Methods: data collection

Measurements were taken on the cranium and face, trunk skeleton and limb bones. Comparable metrics were available on the adult sample. In addition, we recorded the stage of dental emergence and assessed the stage of fusion of long bones and the pelvis.

## Skull

### Brain

Cranial capacity is used as an indirect indicator of brain size. Cranial capacity was determined by filling the brain case with mustard seed three times, recording the contents to the nearest milliliter and taking the average.

### Cranial-facial features

*Linear measurements.* Cranial-facial measurements after Cramer (1977) were taken with spreading and digital calipers and recorded to the nearest millimeter. These measurements span five regions and include (1) cranium: length (g-ob); (2) orbit: interorbital breadth; (3) face: bizygomatic breadth and upper face height; (4) palate: external length; and (5) mandible: maximum length and height.

*Fusion measurements.* We scored the basi-occipital suture (spheno-occipital synchondrosis) as 1, open; 2, partially closed; and 3, closed.

### Teeth

Eruption of the permanent dentition was visually assessed and each tooth was assigned one of the following scores, after Wintheiser, Clauser & Tappen (1977): 1, no emergence; 2, partial emergence, that is, any of the tooth cusps surpassing the bone (alveolus); and 3, full emergence when tooth crowns reach functional occlusion. We paid particular attention to the 'new teeth', the three permanent molars (M1, M2, M3) that have no counterpart in the deciduous or baby teeth. The permanent incisors, canines and premolars are all 'replacement teeth' of the baby teeth.

## Trunk

### Upper torso

*Linear measurements.* Measurements taken on the upper torso include scapular breadth and clavicle length.

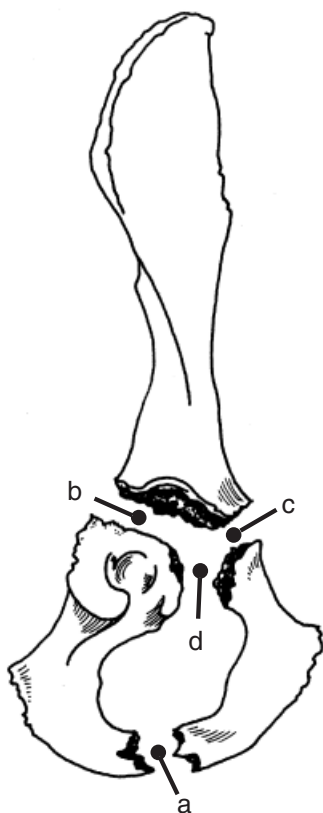
### Pelvis

*Linear measurements.* Measurements on the innominate bone include maximum length, iliac height and breadth and diameter of the acetabulum (after Zihlman *et al.*, 1990).

*Fusion measurements.* Pelvic bone fusion was scored after Wintheiser *et al.* (1977) at four sites: ischio-pubic ramus; ilium to ischium; ilium to pubis; and pubis to ischium. Each site fuses at a different time; hence, each is scored as 1, 2 or 3, as are the long bones. We also noted the fusion of the iliac crest and the distal ischium (see Fig. 1).

## Limbs

*Linear measurements.* We took length measurements on the longest piece, the bone shaft (diaphysis), and took the



**Figure 1** Fusion sites of immature innominate bone: (a) ischio-pubic ramus; (b) ilium to ischium; (c) ilium to pubis; (d) pubis to ischium.

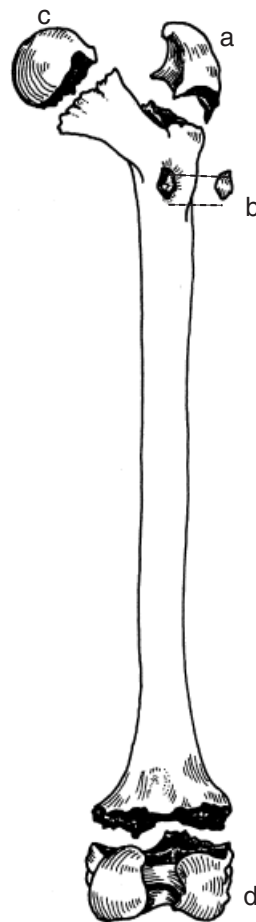
comparable measurements at those points on adult bones (after McFarlin, 2006; Warshaw, 2007).

*Joint fusion measurements.* The long bones of immature chimpanzees ossify in several places at different times, that is, there is more than one growth center. Long bone growth is complete when the bone parts (the epiphyses) fuse to the main shaft and hence serve as an indicator of skeletal maturity. For example, the femur has four sites that fuse (Fig. 2).

We scored fusion as 1, no union; 2, partial union; and 3, full union (after Wintheiser *et al.*, 1977) in the following areas: proximal, medial and distal humerus; proximal and distal radius, ulna, tibia, fibula, femur; greater and lesser trochanters of femur.

### Methods: age class assignment based on dentition

Following our morphological approach, we assigned to each individual a dental age class based on type of maxillary teeth that emerged (e.g. molars and canines). When left versus right sides had different stages of emergence, the less developed dentition was used to establish the individual's age class. This dental age assessment method organizes individuals of different ages into distinct immature subgroups (Table 1).



**Figure 2** Fusion sites of femur: (a) greater trochanter; (b) lesser trochanter; (c) femoral head; (d) distal femur, knee joint.

Classically, dental age classes are defined as follows: Infant, with a partial or full set of deciduous teeth; Juvenile I, with a combination of deciduous and permanent teeth; Juvenile II, with only permanent teeth but not all of them erupted; and adult, with all permanent teeth erupted (e.g. Schultz, 1940, 1969). However, we use three rather than the two juvenile classes of Schultz. This refinement of age classes makes it possible to clarify more precisely skeletal events that are associated with the emergence of molars and permanent canines between the ages of 4 and 12–13 years.

It is well known that dental development with all permanent teeth in place occurs before the body is mature in catarrhine primates (e.g. Schultz, 1942; Kimura & Hamada, 1990; Bolter & Zihlman, 2003). The proximal humerus has not been observed to fuse before the third molar emergence in any ape (e.g. Schultz, 1942, 1944, 1969). We add a Subadult designation when all permanent teeth are erupted but the skeleton is immature and distinguish the adult stage by adding the skeletal element of proximal humeral fusion. In two instances, the proximal humerus was not available for males aged 14.5. Therefore, the basi-occipital suture was used to sort these two males as 'adult', as both had full

**Table 1** Immature Tai chimpanzee *Pan troglodytes verus* sample

Life history stage	Female	Male	Unk	Tooth emergence (maxillary)	Age of known individuals (years)
Infant	1	3	1	Pre-M1	3 weeks to 25 months
Juvenile I	2	3	2	M1 (first permanent molar)	3.8–8.3
Juvenile II	3	1	0	M2 (second permanent molar)	8.3–10.5
Juvenile III	3	2	0	C (permanent canines)	10.5–13.5
Subadult	1	0	0	M3 (third permanent molar)	12.5 <sup>a</sup>
Adult	15	10	0	All teeth emerged; proximal humerus fused	14.5+

<sup>a</sup>The female in this age class is younger than the oldest male in the previous age class.

**Table 2** Chronological age of dental emergence and skeletal fusion in (a) females and (b) males

Life stage	Age range in years <sup>a,b</sup>	Sample (n)	Tooth emergence	Skeletal element fusion occurring during this stage
<i>(a) Females</i>				
Infant	Up to 4 years	1	Deciduous	Pubic ramus
Juvenile I	4–8	2	M1	–
Juvenile II	8–10.5	3	M2	–
Juvenile III	10.5–12.5	3	C	Elbow, hip (acetabulum and femur)
Sub-adult	12.5	1	M3	Knee (fibula), ankle, distal ischium
Young adult	16.5–19.5	2	All	Elements fused: knee (tibia, femur), shoulder, wrist, iliac crest, basi-occipital suture
<i>(b) Males</i>				
Infant	Up to 4 years	3	Deciduous	Pubic ramus
Juvenile I	4–8	3	M1	–
Juvenile II	8–10.5	1	M2	–
Juvenile III	10.5–13.5	2	C	Elbow, hip (acetabulum, trochanters), acromium
Sub-adult	?	0	M3	?
Young adult	14.5	2 <sup>c</sup>	All	Elements fused: knee, ankle, [shoulder?] <sup>d</sup> , wrist, iliac crest, basi-occipital suture

<sup>a</sup>Age rounded to the nearest half-year.

<sup>b</sup>Age rounded to the nearest half-year, and Juvenile II upper range of 10.5 years is estimated from females.

<sup>c</sup>One partially complete.

<sup>d</sup>Neither male had humeral bones; adult classification was applied on the basis of the closed basi-occipital suture.

fusion, whereas no immature individual had a fused basi-occipital (Table 1).

## Methods: data analysis

To establish a chronology of growth, the ages of individuals are matched with the stage of development for each system: cranial, dental, skeletal (Table 2a and b).

Among adults, statistically significant ( $P < 0.05$ ) sex differences can be found in scapular breadth, clavicle length, interorbital and bizygomatic breadth, palatine and mandibular lengths, facial height and cranial capacity, but not in long bones or pelvic measurements. We separated the immature values when available by sex and age classes for those features found to be statistically significant in the adults, and provide them in table format (Table 3a and b).

## Results

The results reveal two aspects of chimpanzee growth: (1) positive correlation between chronological age and stages of development in dental, cranial and skeletal systems; and (2)

variation in the emergence of sex differences in different body regions.

## Individual growth and age

The timing of tooth emergence and skeletal fusion is shown for females and males (Table 2a and b).

## Sex differences in growth

Means, sample sizes and ranges of sexually dimorphic features are shown for immatures and adults (Table 3a and b).

## Discussion

Few reports on primate skeletal development exist for individuals of known age and sex; furthermore, 'there is no single publication that integrates skeletal development with growth and dental and skeletal maturation in the same animals' (Watts, 1986; p. 435). Here, we provide some of the first data on wild chimpanzee somatic maturity that integrate multiple systems from one population. When age and sex are known on collected skeletons, it becomes

**Table 3** Average (a) female and (b) male values, sample size and ranges for sexually dimorphic traits by age class

	Juvenile I	Juvenile II	Juvenile III	Sub-adult	Adult
<i>(a) Females</i>					
Cranial capacity	333.5 (2) 305, 362	343.3 (3) 335–355	347.3 (3) 310–392	342 (1)	352.3 (14) 300–395
Scapular breadth	46.1 (2) 43.1, 49.0	54.7 (2) 48.7, 60.7	63.6 (2) 62.7, 64.4	65.0 (1)	70.2 (10) 61.0–83.5
Mandibular length	87.8 (1)	102.6 (1)	115.3 (3) 113.4–116.2	122.6 (1)	129.7 (11) 119.7–137.9
Clavicle length	75.7 (2) 74.8, 76.5	85.5	100.7 (2) 97.4, 103.9	ND	111.5 (9) 102.8–117.7
Interorbital breadth	10.8 (2) 10.8, 10.8	14.4 (3) 13.7–15.1	16.0 (3) 12.9–19.3	15.9 (1)	18.6 (14) 14.3–22.7
Bizygomatic breadth	93.9 (2) 93.3, 94.6	105 (2) 105.7, 106.0	108.5 (3) 105.0–112.0	121.3 (1)	119.6 (9) 110.0–125.6
Palatine length	37.5 (2) 36.2, 38.8	51.6 (3) 50.1–54.5	53.7 (3) 51.9–57.2	64.5 (1)	64.8 (14) 61.5–71.0
Face height	60.3 (2) 59.5, 61.0	71.7 (3) 66.6–77.8	75.9 (3) 113.4–116.4	86.6 (1)	83.1 (14) 74.6–94.3
<i>(b) Males</i>					
Cranial capacity	379 (3) 340–412	390 (1)	360 (2) 345, 375	ND	383.1 (7) 355–415
Scapular breadth	47.1 (3) 41.6–53.2	ND	72.9 (1)	ND	80.2 (5) 73.6–86.5
Mandibular length	93.4 (2) 86.5, 100.4	111.4 (1)	120.1 (2) 114.6, 125.5	ND	135.7 (7) 130.3–140.8
Clavicle length	81.7 (3) 77.8–86.4	ND 7 (1)	108.8 (1)	ND	121.2 (3) 116.7–123.6
Interorbital breadth	12.1 (3) 9.8–13.6	14	17.4 (2) 16.92, 17.16	ND	21.6 (7) 18.9–25.5
Bizygomatic breadth	94.3 (3) 92.0–97.9	107.8 (1)	112.8 (2) 109.2, 116.5	ND	131.5 (7) 124.0–137.2
Palatine length	43.8 (3) 62.8–65.2	53.0 (1)	55.7 (2) 51.8, 59.7	ND	68.3 (7) 65.0–72.8
Face height	63.7 (3) 62.8–65.2	63.3 (1)	61.8 (2) 56.2, 67.4	ND	89.4 (7) 83.8–99.4

ND, no data.

possible to compare growth between females and males, to correlate physical markers with behavioral observations in the wild, to establish a pattern for the species and to estimate chronological age ranges based on dental and skeletal maturity.

*Correlation of cranial, dental, skeletal dimensions with chronological age.* The Tai immatures enable us to 'match up' dental emergence, bone fusions and morphometrics with age for each life-history stage.

Primate brain growth reaches 90–95% adult size by the emergence of the first permanent molar (Smith, 1989). The Tai specimens follow this model of brain growth. The average of Juvenile I cranial capacity in females is 95% of the adult female value, and the male Juvenile I value is 99% (Table 2a and b).

The dental emergence sequence of the Tai chimpanzees is also consistent with published reports of captive chimpanzees (e.g. Conroy & Mahoney, 1991; Kuykendall, 1996). Tai dental growth differs in the timing, which is slower compared with captives (Zihlman *et al.*, 2004).

Tai skeletal growth also conforms to the well-established pattern of maturity for the chimpanzee skeleton as observed by Todd (1930), Schultz (1940, 1944) and Kerley (1966). This sequence of fusion is elbow (E), hip (H), ankle (A), knee (K), wrist (W), shoulder (S). The lower limb sequence of fusion (H–A–K) is consistent across all primates (Shigehara, 1980). The upper limb fusion sequence of chimpanzees (E–W–S) is common among most primate species, including humans (Shigehara, 1980). Again, what separates the Tai from the previous studies is the timing of maturity. Kerley's (1966) study provides chronological ages for fusions. Although not each immature age is represented, the captive fusion times range from 6 months to over 3 years ahead of the fusion ages for the Tai sample.

The age ranges for the timing of cranial, dental and skeletal growth for wild chimpanzees more accurately reflect the maturational processes under natural conditions.

*Sex differences.* Adult females have narrower upper torsos as expressed in scapular breadth and clavicle length, lower cranial capacities and smaller facial features than

**Table 4** Life-history markers for wild chimpanzees *Pan troglodytes verus*

Field age category	Age in years	Markers Boesch & Boesch-Achermann (2000)		Markers teeth emerged and skeletal elements fused
		External	Behavioral	
Infant	0–5	Small, white tufts	Nurses, dorsal riding	Deciduous teeth; fused pubic ramus; M1 emerge near end
Juvenile	5–10	Half adult body size	Continuous association with mother Less maternal contact	Adult brain size; M1, M2 emerged; skeletal elements of joints unfused; possible sex differences in the upper torso
Adolescence				C and M3 emerged
Female	10–13	Up to 3/4 adult size,		♀Elbow, hip, knee, ankle, acromium, distal ischium fused
Male	10–15	Sexual swelling Testes descend		♂Elbow, hip (partially)
Adult			First reproduction	Sex differences in cranial dimensions
Female	> 13	Larger rump size		♀Wrist, shoulder, iliac crest
Male	> 15	Fully grown		♂Hip, knee, ankle, wrist, shoulder, distal ischium, acromium, iliac crest
Prime adult				
Male	25–40	Loss of head hair		
Old age		Trunk width decrease		
Female	> 40			
Male	> 40		Dominance rank falls	

males. We want to establish when these sexually dimorphic features can be detected in the Taï population. From the small sample size, we suggest that mandibular lengths may diverge during Juvenile II (8–10.5 years). Clavicle length and scapular breadth bimaturity seem to emerge by Juvenile III (10.5–13.5 years), and for these measurements from late juvenility on males either succeed or are completely outside the female ranges. In the scapular and clavicular dimensions of all age classes, males either exceed or are completely outside the female ranges. This finding of sex differences in the shoulder girdle conforms to previous studies showing that the upper torso of chimpanzee males is broader than that of females, based on the larger chest circumferences found in all male anthropoids, including chimpanzees (Schultz, 1956).

It is important to note that pelvic dimensions are NOT sexually dimorphic, whereas upper torso dimensions do differ. This suggests that females have relatively broader pelvic dimensions compared with their upper torso than do males, and these body proportions are evident in juveniles.

With the exception of mandibular length, the remaining sexually dimorphic cranial–facial dimensions do not appear until after the juvenile stages, a pattern established by *Pan troglodytes* specimens from Liberia (Dierbach, 1986). If so, this difference between the sexes would likely correlate with larger male permanent canine teeth and probably heavier temporal muscles, as seen in vervet monkeys (e.g. Bolter & Zihlman, 2003).

*Behavioral markers during development.* Although the life-history labels are used differently, the life stages based on dentition generally conform with what has been proposed by observers of wild chimpanzees based on behavioral criteria (Goodall, 1968, 1986; Pusey, 1978, 1990; Boesch & Boesch-Achermann 2000). Behavioral juvenility

corresponds well with Juvenile I and II in morphology, and adolescence matches temporally with the morphological categories of Juvenile III and sub-adult. Behaviorally, the juvenile stage starts at about age 5 when a younger sibling is born. The juvenile nests alone and is no longer carried or breast-fed. Dentally, juveniles have some permanent molars, nearly adult brain size and no skeletal elements fused except the ischio-pubic ramus. Some sex differences in the torso may become apparent, but body mass is about the same for females and males (Pusey *et al.*, 2005).

The adolescent stage (called Juvenile III and sub-adult in Table 2) starts about age 10 when the youngsters spend more time away from the mother, and males 10–12 years old have been shown to reproduce (Constable *et al.*, 2001; Boesch *et al.*, 2006). During this time, permanent canines and later third molars emerge, pelvic dimensions reach adult size and many long bones fuse in females (in males, these fusions may occur slightly later). Therefore, sperm production begins before somatic growth is complete, a pattern common in male primates and humans (Short, 1976; Matsubayashi & Mochizuki, 1982).

During early adulthood, long bones completely fuse and sex differences in cranial–facial features are established (see Table 4).

*Comparative data: wild chimpanzees across populations.* We highlight three case histories using the Taï sample to illustrate patterns of wild chimpanzee growth. Comparisons between Taï chimpanzees and two individuals of known age from Gombe illustrate the consistency of timing in dental emergence and bone fusion. We summarize the available dento-skeletal growth of six individuals from three other wild populations in Table 5a and b to demonstrate this trend across a larger sample set.

**Table 5** Chronological age of dental emergence and skeletal fusion in (a) females and (b) males

Life stage	Tai population			Other wild populations Locale, age, dental complement and skeletal maturity
	Age range Years <sup>a</sup> Tai	Tooth emerged	Skeletal element fusion occurring during this stage	
<i>(a) Females</i>				
Infant	<4	Deciduous	Pubic ramus	'Amina' from Mahale; 18–19 months, partial deciduous teeth, pubic ramus fused
Juvenile I	4–8	M1	–	'Npei' from Bossou; 6.5 years, M1 emerged, pubic ramus fused only
Juvenile II	8–10.5	M2	–	
Juvenile III	10.5–12.5	C	Elbow, hip (acetabulum and femur),	
Sub-adult	12.5	M3	Knee (fibula), ankle, distal ischium	
Young adult	16.5–19.5	All	Elements fused: Knee (tibia, femur), shoulder, wrist, iliac crest, basi-occipital suture	
<i>(b) Males</i>				
Infant	<4	Deciduous	Pubic ramus	'Plato' from Gombe 2.5 years, all deciduous emerged, pubic ramus fused only
Juvenile I	4–8	M1	–	
Juvenile II	8–10.5	M2	–	'Flint' from Gombe 8.5 years, M1 and M2 emerged, pubic ramus fused only
Juvenile III	10.5–13.5	C	Elbow, hip (acetabulum, trochanters), acromium	
Sub-adult	?	M3	?	'Michaelmas' from Gombe 13.0 years, all teeth emerged, pubic ramus, elbow fused, partial fusion of acetabulum <sup>b</sup> 'McDee' from Gombe 13.4 years, all teeth emerged, all elements fully fused except knee, shoulder, wrist, iliac crest, distal ischium and basi-occipital suture
Young adult	14.5+	All	Elements fused: knee, ankle, shoulder, wrist, iliac crest, basi-occipital suture	

<sup>a</sup>Age rounded to the nearest half-year.

<sup>b</sup>Right side only; left innominate injured.

### Case study #1: male 8.2 years ('Lefkas'), female 8.3 years ('Xindra') and Gombe male 8.5 years ('Flint')

In these three 8-year olds, the maxillary M2's have emerged, but their long bone fusion is incomplete. The pubic ramus, however, is fully fused in all three individuals. In captive individuals, by 8-year of age, skeletal elements (distal humerus, medial epicondyle females and males; proximal ulna, hip joint and lesser trochanter females) are already fusing (Kerley, 1966) (see also Table 6).

### Case study #2: female 12.5 years ('Zerlina') and male 13.5 years ('Clyde')

The oldest immature female and male from the collection highlight the development of sex differences. The 12.5-year-old female appears more mature than the 13.5 male.

'Zerlina' has all her permanent teeth, with M3's barely rising above the alveolus, making her a very young subadult. The acetabulum (tri-radiate complex) is completely fused,

with no fusion scars. The distal ischium is partially fused, and the iliac crest is unfused. The elbow joint (distal humerus, proximal radius and ulna) is fully fused, and also the proximal epiphyses of the femur and the acromial process on the scapula. Proximal and distal fibula, and distal tibia are partially fused. Five epiphyses, the proximal tibia and humerus, distal femur, radius and ulna are unfused. Measurements of long bone and pelvis lengths, and craniofacial features fall within the adult values.

'Clyde' is less mature, even though 1 year older than 'Zerlina.' His M3's are not emerged or visible. His acetabulum is in the process of completing fusion. The border of the ilium and ischium is fully fused, as is that between the ilium and pubis. A fusion scar is still visible. The ischium-pubis is partially fused, with a gap at the very top of the obturator foramen.

Only parts of 'Clyde's' elbow (medial and distal humerus) are fused; the proximal ulna is mostly fused, but the proximal radius is only partially fused on the left side (the right side is completely unfused). The greater trochanter is only partially fused. The acromial process on the left scapula

**Table 6** Wild and captive chimpanzees *Pan troglodytes* compared in dental emergence<sup>a</sup> and long bone fusions<sup>b</sup>

	Wild chimpanzees (Tai)	Captive chimpanzees
M1 emergence	~4 years	2.7–4.1 <sup>c</sup>
M2 emergence	~8 years	5.3–7.3 <sup>d</sup>
M3 emergence	~12.5 years	No data (10.5 <sup>e</sup> )
Distal humerus fully fused	F <sup>f</sup> : by 12.5 years M: by 13.5 years	F: by 9 years M: by 8 years
Acetabulum fully fused	F <sup>g</sup> : by 12.5 years M: by 14.5	F: by 9 years M: by 13 years
Distal femur fully fused	F: by 16.5 M: by 14.5	F: by 10 years M: by 13 years
Humeral head fully fused	F: by 16.5 M: by 14.5 <sup>h</sup>	F: between 9–18 years <sup>i</sup> M: between 14–18 years <sup>i</sup>

<sup>a</sup>Modified from Zihlman *et al.* (2004); in making the captive – wild comparison, we used maxillary molars and added 4 months to the alveolar emergence observed on the skeletons, to approach comparability to the observations on dental emergence through the gingiva on live animals. The 4 months from alveolar margin to gingival emergence are based on a study by Kelley & Smith (2003).

<sup>b</sup>Kerley (1966). Based on nine females aged 6, 7, 9 ( $n=2$ ), 10, 12, 13 ( $n=2$ ), 14; and four males aged 6, 8, 13, 14.

<sup>c</sup>10–90% range Conroy & Mahoney (1991).

<sup>d</sup>10–90% range Conroy & Mahoney (1991).

<sup>e</sup>No data available, but estimated from crown formation times (Schwartz *et al.*, 2000).

<sup>f</sup>No data available for wild 10.5-year female.

<sup>g</sup>No data available for wild 10.5-year female.

<sup>h</sup>Estimated.

<sup>i</sup>Four females aged 12, 13 ( $n=2$ ) and 14 years have a partially fused proximal humerus, while 9, 18, 19, 20 and 21 ( $n=2$ ) year olds have fully fused proximal humeral joints.

<sup>j</sup>One male aged 17 years has only a partially fused proximal humerus, while the 14, 16, 18 ( $n=2$ ) and 23-year olds are fully fused.

is near to complete fusion but the right side is completely unfused. The remainder of the epiphyses, 10 in all, are completely unfused. In length measurements, the majority of his linear dimensions fall below the adult range. These include humerus length, scapular breadth, innominate length, iliac breadth, interorbital and bizygomatic breadth, palatine length, upper face height and mandibular length.

### Case study #3: male 13.5 years ('Clyde') and Gombe male 13.4 years ('McDee')

These two 13-year olds show that significant skeletal growth occurs late in wild male chimpanzees. 'McDee', who died of polio in 1966 (Goodall, 1986), is comparable in age to 'Clyde', although further along in dental, skeletal and linear growth measurements than the Tai male. 'McDee's' permanent teeth have erupted and basically all occlude functionally. Most epiphyses are fused. Basi-occipital and proximal fibula are partially fused. The wrist and remaining knee elements, iliac crest and proximal humerus are not fused. 'McDee' lies outside adult ranges for iliac breadth, interorbital breadth and palatine length. These two skeletons show variation in post-cranial maturity; however, both males at age 13 are clearly still immature in the skeleton. More skeletal material on males will clarify the range of variation across populations.

*Mahale, Tanzania and Bossou, Guinea.* Known individuals from other sites are consistent with the Tai and Gombe chimpanzees. From Mahale, a female 'Amina' age 18–19 months has all deciduous teeth fully emerged, except

for the lower canines, which are only partially emerged, and has the ischio-pubic ramus fused (Yasui & Takahata, 1983). 'Amina' fits well into the Infant (0–3.8 years) category. From Bossou a, 6.5-year-old female 'Npei' has M1 but no M2; only the ischio-pubic ramus is fused (Matsuzawa *et al.*, 1990); this individual fits well into Juvenile I (age 4–8 years).

*Comparative data: captive and wild chimpanzees.* Previous studies have shown that captive chimpanzees mature earlier in body mass (Pusey, 1978; Hamada *et al.*, 1996; Leigh & Shea, 1996; Pusey *et al.*, 2005), in trunk length (Hamada & Udono, 2002), in limb length (Kimura & Hamada, 1996), in dental eruption (Zihlman *et al.*, 2004) and in reproduction (Boesch & Boesch-Achermann, 2000). Maturation times may be extended from 1 to over 3 years in wild chimpanzees.

The skeletons of Tai and Gombe individuals further confirm accelerated growth of captives. Based on 63 known-aged captive chimpanzees, Schultz (1940) found long bone fusion to begin at age seven (elbow) and finish at age 11 (proximal humerus). A study of 30 chimpanzees from birth through age 35 years scored epiphyseal union based on radiographic observations and direct examination of skeletons (Kerley, 1966). By age 6, the distal humerus is partially fused, and fusion is completed by 8 years. The acetabulum begins fusing by age 7 and is completely fused by age 9 years in females. By age 10, the acromial process is fused. All these ages are earlier than those in the wild. For example, relative to captive chimpanzee data, 'Zerlina' (12.5 years) would be estimated at 9–10 years old, underestimating by 3 years, about 30%.

The dentition follows a pattern similar to the skeleton, and more data points show that the gap widens between captive and wild chimpanzees during the Juvenile II and III

stages (Table 6). The eruption of M1 at about 4 years marks the Juvenile I stage, which is within but at the late end of the captive range (Conroy & Mahoney, 1991). During the Juvenile II and III stages, captive chimpanzees accelerate their growth and attain maturity sooner than wild individuals. For example, 'Xindra' at 8.3 years (Juvenile II) has newly emerged M2's whereas 90% of the captive chimpanzees have M2's emerged by 6.2 years, and many skeletal elements fused. 'Zerlina's' skeleton also demonstrates that older wild individuals mature more slowly than their captive counterparts.

### Why the captive-wild difference?

Explanations have been offered for the differences in the tempo of physical growth in wild versus captive primates. For instance, better nutrition and health may accelerate growth rates in captive and provisioned primates (e.g. Mori, 1979; Altmann, Altmann & Hausfater, 1981; Phillips-Conroy & Jolly, 1988; Kimura & Hamada, 1996). Another suggestion for the slower tempo of wild primate growth is that this is a strategy in nutrient-poor environments that spreads out the metabolic needs over a longer immature period, thereby reducing risk of starvation and increasing overall survival (Janson & van Schaik, 1993, p 65).

By contrast, we argue that energy requirements for physical growth in the wild might account for divergent captive/wild maturity. Energy allocation for motor activity has been vastly underestimated for juveniles (Altmann, 1998). Juvenile chimpanzees travel independently on the ground for very long distances (daily average, 4–11 km in Tai chimpanzees; Boesch & Boesch-Achermann, 2000), climb in trees and forage for food, as well as navigate an intense social setting, which require large amounts of metabolic energy.

After 5 years of age, about the time of weaning, juvenile wild chimpanzees are no longer carried and fed by the mother (Goodall, 1986; Boesch & Boesch-Achermann, 2000). As a consequence, the survival and social demands of young juveniles require more energy for daily life than captive counterparts. In captivity, food is provided, predators are absent and cage conditions are controlled and animals have limited social contacts (e.g. Hamada *et al.*, 1996). In contrast, wild individuals forage daily, spend hours in quadrupedal terrestrial travel and climbing trees (Doran, 1989, 1996), virtually nonexistent in captive chimpanzees. Young chimpanzees also regularly encounter and interact with members of their large (*c.* 50) fission/fusion communities (Goodall, 1986; Boesch & Boesch-Achermann, 2000). Precisely during this stage, the gap between wild and captive widens because wild juveniles are expending enormous amounts of energy for these activities and consequently have less energy available for growth. After about 10 years of age, young chimpanzees from Kibale become adult-like in locomotor skills (Pontzer & Wrangham, 2006), about the age that significant fusion of skeletal elements is underway in the Tai sample.

The impact of reduced activity on physical growth, body mass and reproduction may also apply to two groups of wild baboons *Papio cynocephalus* living in the same region but

under different conditions (Altmann *et al.*, 1993). Hook's troop covered 8–10 km a day while foraging around their home range. The Lodge group residing near a tourist lodge traveled less than 4 km a day and foraged regularly on the leftovers of human meals. Both groups consumed similar numbers of calories per day, but the females of the Lodge group had greater body mass and fat, and conceived their first offspring on average 1 year before the Hook group. Infants in the Lodge group grew faster and were weaned earlier. This 'natural experiment' illustrates the central role of activity in the energy budget, and consequently in the tempo of growth, development and reproduction.

### Application of known ages for wild chimpanzees

Both museum and field researchers must use a life-history scheme that is as accurate as possible. The chronology of growth for wild chimpanzees provides a forensic framework to estimate ages of skeletons housed in museum collections (e.g. Shea, 1981). Unknown individuals (skeletons) retrieved from chimpanzee field sites also can be estimated for age, increasing the likelihood of post-mortem identification of group members.

One of the most important insights provided by the Tai collection combined with the few wild specimens available from Gombe, Bossou and Mahale is that additional immature skeletal data are crucial for fully establishing variation in the chimpanzee species. Furthermore, some age classes are single data points, and only when field researchers collect specimens after death will we be able to fill in the gaps. Such skeletal and dental data provide more accurate characterization of chimpanzee growth and a foundation that better highlights similarities and differences in growth between chimpanzees and *Homo sapiens*, and between wild chimpanzee populations and maturation in fossil hominids.

### Summary and conclusions

The Tai population provides a unique dataset for the physical growth of immature wild chimpanzees. The timing of maturation of the dentition and skeleton reveals a chronological age sequence that seems to differ between females and males and that represents a shared pattern across wild populations. Captive chimpanzees reach skeletal and dental maturity before wild chimpanzees, and in some instances this difference spans several years. In the wild, day-to-day life in a natural habitat demands more energy output for locomotion, feeding and social activities than in captive environments; hence, for young wild chimpanzees less energy can be devoted to physical growth. The absolute age ranges for these life stages in the wild and the correlated physical markers in hard tissues may help future researchers to estimate ages in wild chimpanzee skeletal collections and provide a comparative framework similar to data available for *H. sapiens* (e.g. Scheuer, Black & Liversidge, 2004). Finally, much remains to be learned about immaturity in wild chimpanzees that cannot be derived from captive

individuals, which further underscores the importance of conserving our closest living relatives.

## Acknowledgements

We thank the Ministry of the Environment and Forests, the Ministry of Research of Côte d'Ivoire, the directorship of the Tai National Park, and the Centre Suisse de Recherches Scientifiques (CSRS) in Abidjan for their constant and faithful support of our long-term research project during all those years and for providing the permits to work with the chimpanzee specimens; Gustl Anzenberger, Karin Isler, Kris Carlson and the Institut of Anthropology at the University of Zürich for curation; Dr Jane Goodall and the Tanzanian Government, especially the Director of Tanzania National Parks and Director of Wildlife, and Anthony Collins and the Tanzanian Field Staff at Gombe for the Gombe material. We appreciate the comments of Drs T. Grand and J.M. Lowenstein, and the illustrations of Carol Underwood. The work was supported in part by the Leakey Foundation and by the University of California, Santa Cruz, Faculty Research Committee and Social Sciences Division.

## References

- Altmann, J., Altmann, S. & Hausfater, G. (1981). Physical maturation and age estimates of yellow baboons, *Papio cynocephalus*, in Amboseli National Park, Kenya. *Am. J. Primatol.* **1**, 389–399.
- Altmann, J., Schoeller, D., Altmann, S., Muruthi, P. & Sapolsky, R. (1993). Body size and fatness of free-living baboons reflect food availability and activity levels. *Am. J. Primatol.* **3**, 149–161.
- Altmann, S. (1998). *Foraging for survival. Yearling baboons in Africa*. Chicago: University of Chicago Press.
- Boesch, C. & Boesch-Achermann, H. (2000). *The chimpanzees of the Tai forest: behavioural ecology and evolution*. Oxford: Oxford University Press.
- Boesch, C., Kohou, G., Néné, H. & Vigilant, L. (2006). Male competition and paternity in wild chimpanzees of the Tai forest. *Am. J. Phy. Anthropol.* **130**, 103–115.
- Bogin, B. (1999). *Patterns of human growth*. Cambridge: Cambridge University Press.
- Bolter, D.R. & Zihlman, A.L. (2003). Morphometric analysis in wild-caught vervet monkeys (*Cercopithecus aethiops*), with implications for growth patterns in Old World monkeys, apes and humans. *J. Zool. (Lond.)* **260**, 99–110.
- Bolter, D.R. & Zihlman, A.L. (2007). Primate growth and development. A functional and evolutionary approach. In *Primates in perspective*: 408–422. Campbell, C.J., Fuentes, A., MacKinnon, K.C., Panger, M. & Bearder, S.K. (Eds). New York: Oxford University Press.
- Conroy, G.C. & Mahoney, C.J. (1991). Mixed longitudinal study of dental emergence in the chimpanzee, *Pan troglodytes* (primates, pongidae). *Am. J. Phy. Anthropol.* **86**, 243–254.
- Constable, J.L., Ashley, M.V., Goodall, J. & Pusey, A.E. (2001). Noninvasive paternity assignment in chimpanzees. *Mol. Ecol.* **10**, 1279–1300.
- Cramer, D.L. (1977). *Cranial-facial morphology of Pan paniscus. A morphometric and evolutionary appraisal. Contrib. Primat.*, Vol. 10. Basel: S. Karger.
- Dierbach, A. (1986). Intraspecific variability and sexual dimorphism in the skulls of *Pan troglodytes verus*. *Hum. Evol.* **1**, 41–50.
- Doran, D. (1989). *Chimpanzee and pygmy chimpanzee positional behavior*. Ann Arbor, MI: University Microfilm International.
- Doran, D. (1996). Comparative positional behavior of the African apes. In *Great ape societies*: 213–224. McGrew, W.C., Marchant, L.F. & Nishida, T. (Eds). Cambridge: Cambridge University Press.
- Formenty, P., Boesch, C., Dind, F., Donati, F., Steiner, C., Wyers, M. & Le Guenno, B. (1999). Outbreak of Ebola in wild chimpanzees. *J. Infect. Dis.* **179** (Suppl. 1), 120–129.
- Gavan, J.A. (1953). Growth and development of the chimpanzee. A longitudinal comparative study. *Hum. Biol.* **25**, 93–144.
- Gavan, J.A. (1971). Longitudinal, postnatal growth in chimpanzee. In *The chimpanzee*: 46–102. Bourne, G.H. (Ed.). Basel: Karger.
- Goodall, J. (1968). Behaviour of free-living chimpanzees of the Gombe Stream area. *Anim. Behav. Monogr.* **1**, 163–311.
- Goodall, J. (1986). *The chimpanzees of Gombe: patterns of behavior*. Cambridge, MA: Harvard University Press.
- Hamada, Y. & Udono, T. (2002). Longitudinal analysis of length growth in the chimpanzee (*Pan troglodytes*). *Am. J. Phy. Anthropol.* **118**, 268–284.
- Hamada, Y., Udono, T., Teramoto, T. & Sugawara, T. (1996). The growth pattern of chimpanzees: somatic growth and reproductive maturation in *Pan troglodytes*. *Primates* **37**, 279–295.
- Herbinger, I., Boesch, C. & Rothe, H. (2001). Territory characteristics among three neighboring chimpanzee communities in the Tai National Park, Côte d'Ivoire. *Int. J. Primatol.* **22**, 143–167.
- Janson, C.H. & van Schaik, C.P. (1993). Ecological risk aversion in juvenile primates: slow and steady wins the race. In *Juvenile primates. Life history, development, and behavior*: 57–74. Pereira, M.E. & Fairbanks, L.A. (Eds). Oxford: Oxford University Press.
- Kelley, J. & Smith, T. (2003). Age at first molar emergence in early Miocene *Afropithecus turkanensis* and life-history evolution in the Hominoidea. *J. Hum. Evol.* **44**, 307–329.
- Kerley, E.R. (1966). Skeletal age changes in the chimpanzee. *Tulane Stud. Zool.* **13**, 71–80.
- Kimura, T. & Hamada, Y. (1990). Development of epiphyseal union in Japanese macaques of known chronological age. *Primates* **31**, 79–93.

- Kimura, T. & Hamada, Y. (1996). Growth of wild and laboratory born chimpanzees. *Primates* **37**, 237–251.
- Kuykendall, K. (1996). Dental development in chimpanzees (*Pan troglodytes*): the timing of tooth calcification stages. *Am. J. Phy. Anthropol.* **99**, 135–157.
- Leendertz, F., Lankester, F., Guislain, P., Néel, C., Drori, O., Dupain, J., Speede, S., Reed, P., Wolfe, N., Loul, S., Mpoudi-Ngole, V., Peeters, M., Boesch, C., Pauli, G., Ellerbrok, H. & Leroy, E. (2006). Anthrax in Western and Central African great apes. *Am. J. Primatol.*, **68**, 928–933.
- Le Guenno, B., Formenty, P., Wyers, M. & Boesch, C. (1995). Isolation and partial characterization of a new Ebola strain. *Lancet* **345**, 1271–1274.
- Leigh, S.R. & Shea, B.T. (1996). Ontogeny of body size variation in African apes. *Am. J. Phy. Anthropol.* **99**, 43–65.
- Matsubayashi, K. & Mochizuki, K. (1982). Growth of male reproductive organs with observation of their seasonal morphological changes in Japanese monkeys (*Macaca fuscata*). *Jpn. J. Vet.* **44**, 891–902.
- Matsuzawa, T., Sakura, O., Kimura, T., Hamada, Y. & Sugiyama, Y. (1990). Case report of the death of a wild chimpanzee (*Pan troglodytes verus*). *Primates* **31**, 635–641.
- McFarlin, S.C. (2006). *Ontogenetic variation in long bone microstructure in catarrhines and its significance for life history research*. PhD thesis, The City University of New York.
- Mori, A. (1979). Analysis of population changes by measurement of body weight in the Koshima troop of Japanese monkeys. *Primates* **20**, 371–398.
- Nishida, T. (Ed.) (1990). *The chimpanzees of the Mahale mountains: sexual and life history strategies*. Tokyo: University of Tokyo Press.
- Nissen, H.W. & Riesen, A.H. (1964). The eruption of permanent dentition of chimpanzee. *Am. J. Phy. Anthropol.* **22**, 285–294.
- Phillips-Conroy, J. & Jolly, C. (1988). Dental eruption schedules of wild and captive baboons. *Am. J. Primatol.* **15**, 17–29.
- Pontzer, H. & Wrangham, R.W. (2006). Ontogeny of ranging in wild chimpanzees *Int. J. Primatol.* **21**, 295–309.
- Pusey, A.E. (1978). *The physical and social development of wild adolescent chimpanzees (Pan troglodytes schweinfurthii)*. PhD thesis, Stanford University, Palo Alto.
- Pusey, A.E. (1990). Behavioural changes at adolescence in chimpanzees. *Behaviour* **115**, 203–246.
- Pusey, A.E., Oehlert, G.W., Williams, J.M. & Goodall, J. (2005). Influence of ecological and social factors on body mass of wild chimpanzees. *Int. J. Primatol.* **26**, 3–31.
- Scheuer, L., Black, S. & Liversidge, H. (2004). *The juvenile skeleton*. Amsterdam: Elsevier Academic Press.
- Schultz, A.H. (1940). Growth and development of the chimpanzee. *Contrib. Embryol.* **28**, 1–63.
- Schultz, A.H. (1942). Growth and development of the proboscis monkey. *Bull Mus. Comp. Zool.* **89**, 279–323.
- Schultz, A.H. (1944). Age changes and variability in gibbons: a morphological study on a population sample of a man-like ape. *Am. J. Phy. Anthropol.* **2**, 1–129.
- Schultz, A.H. (1956). Postembryonic changes. *Primatologica* **1**, 887–964.
- Schultz, A.H. (1963). Age changes, sex differences, and variability as factors in the classification of primates. *Viking Fund publ. Anthropol.* **37**, 85–115.
- Schultz, A.H. (1969). The skeleton of the chimpanzee. *Chimpanzee* **1**, 50–103.
- Schwartz, G.T., Reid, D.J., Dean, C. & Chandrasekera, M.S. (2000). Aspects of tooth crown development in common chimpanzees (*Pan troglodytes*) with a note on the possible role of sexual dimorphism in canine growth. *Proceedings of 11th International Symposium on Dental Morphology, Oulu, Finland*. pp. 323–337.
- Shea, B.T. (1981). Relative growth of the limbs and trunk in the African apes. *Am. J. Phy. Anthropol.* **56**, 179–201.
- Short, R.V. (1976). The evolution of human reproduction. *Proc. Roy. Soc. Lond. Ser. B* **195**, 3–24.
- Shigehara, N. (1980). Epiphyseal union, tooth eruption, and sexual maturation in the common tree shrew, with reference to its systematic problem. *Primates* **21**, 1–19.
- Smith, B.H. (1989). Dental development as a measure of life history in primates. *Evolution* **43**, 683–688.
- Todd, T.W. (1930). Comparative youth. *Child Dev.* **1**, 79–89.
- Tutin, C. (1996). Reproductive success story: variability among chimpanzees and comparisons with gorillas. In *Chimpanzee cultures*: 181–193. Wrangham, R., McGrew, W., de Waal, F. & Heltne, P. (Eds). Cambridge, MA: Harvard University Press.
- Warshaw, J. (2007). *Primate bone microstructural variability: relationships to life history, mechanical adaptation and phylogeny*. PhD thesis, The City University of New York.
- Watts, E.S. (1971). *A comparative study of skeletal maturation in the chimpanzee and rhesus monkey and its relationship to growth and sexual maturity*. PhD thesis, University of Pennsylvania, Philadelphia.
- Watts, E.S. (1986). Skeletal development. In *Comparative primate biology: reproduction and development*: 415–439. Dukelow, W. & Erwin, J. (Eds). New York: Alan R. Liss.
- Wintheiser, J.G., Clauser, D.A. & Tappen, N.C. (1977). Sequence of eruption of permanent teeth and epiphyseal union in three species of African monkeys. *Folia Primatol.* **27**, 178–197.
- Yasui, K. & Takahata, Y. (1983). Skeletal observation of a wild chimpanzee infant (*Pan troglodytes schweinfurthii*) from the Mahale Mountains, Tanzania. *African Study Monogr.* **4**, 129–138.
- Zihlman, A.L., Bolter, D.R. & Boesch, C. (2004). Wild chimpanzee dentition and its implications for assessing life history in immature hominin fossils. *Proc. Natl. Acad. Sci. USA* **101**, 10541–10543.
- Zihlman, A.L., Morbeck, M.E. & Goodall, J. (1990). Skeletal biology and individual life history of Gombe chimpanzees. *J. Zool. (Lond.)* **221**, 37–61.